



A2005-02674

North Carolina Department of Health and Human Services  
Postmortem Medicolegal Examination  
Office of the Chief Medical Examiner  
Chapel Hill, NC 27599-7580  
Telephone (919) 966-2253

**REPORT OF AUTOPSY EXAMINATION**

---

**AUTOPSY NUMBER:** B05-1518                      **CASE NUMBER:** 2005-4631  
**DECEDENT:** Melody Wiggins  
**AGE:** 29                      **RACE:** Black                      **SEX:** Female  
**Authorized by:** Dr. John Butts                      **Received from:** Edgecombe County  
**Date of Autopsy Examination:** 05/31/05                      **Time:** 10:00 a.m.  
**Body identified by:** Accompanying papers, law enforcement, dental records  
**Persons present at autopsy:** Pat Matthews, SBI, Lt. Shane Guyand and Robert Tender, Edgecombe County Sheriff's Department

---

**PATHOLOGICAL DIAGNOSES**

Blunt force trauma to the head with multiple fractures of the skull  
Multiple stab and cutting injuries, chest, arms, back and buttocks

---

**CAUSE OF DEATH:** Blunt force head trauma

---

The facts stated herein are correct to the best of my knowledge and belief.

  
\_\_\_\_\_  
John D. Butts M.D., Pathologist                        
Date

**AUTOPSY NUMBER: B05-1518**

**DECEDENT: Melody Wiggins**

**CASE NUMBER: 2005-4631**

## **EXTERNAL DESCRIPTION**

**Body condition:** Moderate decomposition

**Length:** 68 inches

**Weight:** 152 pounds

**Body Heat:** Cool

**Rigor:** Undetectable

**Livor:** Undetectable

**Hair:** Not present with body but in custody of Matthews, SBI, appears to be dark and kinky

**Eyes:** Absent

**Teeth:** Present

**Facial hair:** Unknown

These remains are received in a light duty white body bag inside of a blue heavy duty body bag. The decedent is lying on her back. Bags are present on the hands and feet. She is wearing a pair of black pants that are pulled down to the mid-thigh region and show cutting or tearing of the portions of the legs. She is wearing a pair of black panties half of which is partly folded down but they are otherwise in place. There is a black bra present which is pulled up towards the chin. A bandaid is present over a small approximately 1" shallow cut on the anteromedial surface of the right lower leg just above the ankle. The feet are dirty. There is residual metallic reddish polish on the toenails. The nails of the fingers are bitten down and the fingers are covered with dirt and some blood.

Bits of plant debris are present on the body. Insects are present. Large beetles are numerous on the body and a number of maggots are active particularly in the head region. There has been significant skeletonization of the right side of the head and face. Some skin remains on the undersurface of the chin and there is dry darkened skin on the left ear. Skin is present on the anterior neck and around to the right upper chest region. Scattered across other body surfaces are various foci of insect injury.

## **EVIDENCE OF INJURY**

Evidence of blunt force trauma to the skull is noted. The mandible is fractured centrally, the maxilla is separate from the upper part of the jaw and tooth #9 is loose with a fracture line extending through its socket. Areas of apparent impact injury are noted on the right temple region with considerable fragmentation. The skull and its pieces are cleaned to be then glued back in place.

CASE NUMBER: 2005-4631

Following cleaning and reconstruction of the skull it is noted that there is an area of concentrated roughly elliptical fracturing of the right temporoparietal area measuring approximately 2 1/4" x 2 1/2". There is a line of fractures centrally that approximates the temporoparietal suture line with additional fractures extending downwards. The upper portion of the defect shows multiple fractures and some small portions are missing superiorly. The fracture line extends through the upper zygoma, as well as laterally and anteriorly. There is diastatic fracture of the coronal suture that extends across the midline, down on the left to another fracture that extends to the left orbit. An additional fracture line extends from the midline of the left frontal bone downwards and to the right just above the orbit on the right. Fractures lines extend through both maxillae from the orbital rims to the nasal aperture and another fracture line is present below the nasal aperture extending to the alveolar ridge. The mandible is fractured in the midline as noted.

**CUTTING INJURIES:**

There are multiple stab and cutting injuries present on the body. These include two somewhat transverse cutting injuries of the buttock region. The one on the right is located approximately 30" up from the heel in the mid portion of the buttock and measures 3" in length and on the corresponding left buttock area approximately 31" up from the heel is a 2 1/2" cut. It extends in the immediate subcutaneous fatty tissues.

On the back of the left forearm is a 2 1/4" incised wound. It can be probed a fraction of an inch.

On the right upper back 1/2" to the right of midline is a slightly crescent shaped 1 1/2" cut. It is 52" up from the heel. This does not probe any significant distance into the underlying tissues.

On the left anterior thigh is a 1 1/4" defect approximately 28" up from the heel. There has been marked loss of tissues in this area secondary to scavenger activity and it is not clear whether this was a wound from a previous assault or entirely artifactual.

Another stab wound is present located on the left upper hip region approximately 34 1/2" up from the heel. This is vertically oriented and measures 1 3/4" in length. It probes into the tissues of the left hip area approximately 3 1/2".

There is extensive injury to the anterior neck and right upper chest region. What appears to be a 1 3/4" wound is present within the area of the right breast. There is exposure of the rib cage and the right anterior chest cavity. It is not clear however whether this is a cutting wound or scavenger artifact.

Wounds are present involving the hands. There is a 2 1/2" cut of the palm on the left hand extending from near the base of the thumb up to the web between the thumb and 1<sup>st</sup> finger. There is a shallow incised 1/2" wound of the palmar side of the right thumb. A number of scratches are noted of the right forearm and along the wrist.

**AUTOPSY NUMBER: B05-1518**

**DECEDENT: Melody Wiggins**

**CASE NUMBER: 2005-4631**

On the left hand there is a 1" cut in the web between the thumb and 1<sup>st</sup> finger. There is a 3/4" cut of the palmar side of the thumb near the last interphalangeal joint. At the base of the thumb there is a small 1/4" cut and superior to that medial to the base of the thumb is a 3/8" cut. A pair of cuts measuring 3/8 and 1/2" respectively are present over the surface of the 1<sup>st</sup> phalange of the middle and index fingers.

### **ADDITIONAL PROCEDURES**

**Radiographs:** X-rays reveal no evidence of any bullets.

**Microbiology:** None

**Chemistry:** None

**Evidence collected:** Clothing, blood stain sample, partial sexual assault evidence collection kit prepared for authorities. Included in the latter is a blood card, anal swabs and smears, vaginal swabs and smears and a pubic hair sample.

**Personal Effects Disposition:** Turned over to authorities.

### **INTERNAL EXAMINATION**

**Body cavities:** The pleural and pericardial cavities show evidence of decomposition and scavenging activities. On the right side there is discoloration and absence of portions of the heart and right lung. The left lung appears intact with some decompositional fluid being present. The peritoneal cavity shows decompositional change.

**Cardiovascular system:** Heart: 230 gms. The coronaries were identified and appear normal and show no atherosclerosis. Much of the right ventricle of the heart is absent and the tissues are softened. The remaining portion of the left ventricle appears unremarkable. The valves appear normally formed. The aorta and its major branches are intact without atherosclerosis.

**Neck:** The hyoid bone is identified. Portions of the laryngeal cartilage are found. The remainder of the neck structures are decomposed or absent.

**Respiratory tract:** Lungs: Right 160 gms, Left 250 gms. The left lung appears intact. The right lung shows damage secondary to scavenging. It is not clear whether other injuries are present.

**Gastrointestinal tract:** The GI tract shows autolytic changes. The esophagus is identified and is unremarkable. The appendix is identified. The stomach appears to have been empty.

**Liver:** 640 gms. The gallbladder is not definitely identified.

**Pancreas:** Autolyzed but appears in normal limits.

**AUTOPSY NUMBER: B05-1518**

**DECEDENT: Melody Wiggins**

**CASE NUMBER: 2005-4631**

**Spleen:** 100 gms. Soft.

**Adrenal glands:** Identified.

**Urinary tract:** Kidneys: Right 120 gms, Left 120 gms. The cortical surfaces are smooth. The ureters appear to have been intact. The bladder is empty.

**Reproductive tract:** Uterus, tubes and ovaries are identified. The uterine cavity is filled with purplish material. Some reddish material was identified in the vagina. The external genitalia appear unremarkable.

**Musculoskeletal system:** Injury as described.

**Immunologic system:** No lymphadenopathy noted.

**Head:** Scalp: Largely absent. Skull: Shows fractures as described. Brain: Absent.

#### **IDENTIFICATION NOTE:**

On June 3, 2005 a set of dental x-rays and written notation is brought to the Office of the Chief Medical Examiner by Detective Jean Harrell of the Edgecombe County Sheriff's Department. The x-rays consists of a panorex film with the label Dental Care Center, 101 Wayfare Court, Rocky Mount, NC 27801, labeled with the decedent's name and "Duplicate 1/17/01" as well as a set of bite wing films, duplicate, from the same date. Comparison of those x-rays with the dentition present on the body of the decedent reveals excellent correspondence with the dentition present in the remains. The dentition is additionally reviewed by Alan D. Samuelson DDS, who concurs that the x-rays positively identify these remains as being those of Melody Wiggins.

#### **MICROSCOPIC EXAMINATION**

**Lungs:** Autolyzed.

**Liver:** Autolyzed but no apparent scarring or fatty change noted.

**Kidneys:** Autolyzed but appears within normal limits.

#### **SUMMARY AND INTERPRETATION**

This was an initially unknown woman later identified as Melody Wiggins, 29 years of age, whose body was found in a wooded area adjacent to a field in Edgecombe County.

Autopsy examination revealed evidence of blunt force trauma to the head and cutting injuries to the chest, arms, hands, back and buttocks. The skull fractures were extensive and indicative of blows to the right side of the head. In my opinion, her death was the result of these blunt force injuries.

State of North Carolina

Office of the Chief Medical Examiner

Chapel Hill, North Carolina 27599-7580

Name of Decedent: Melody Wiggins

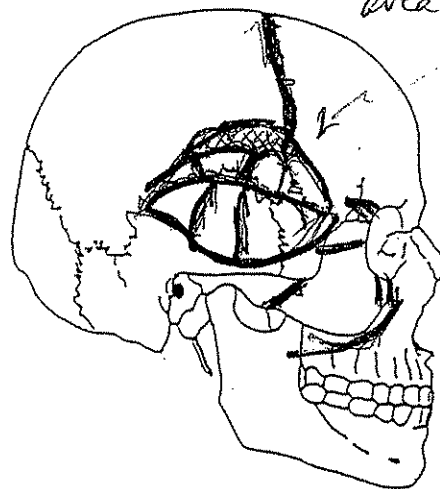
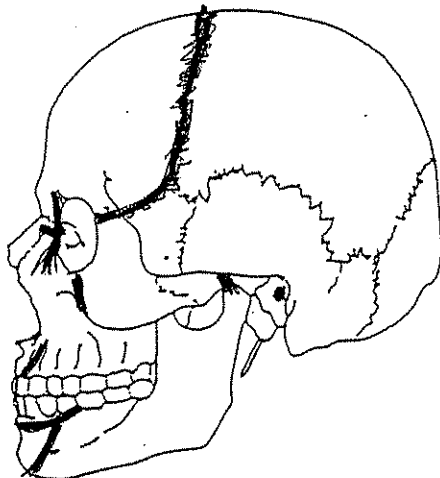
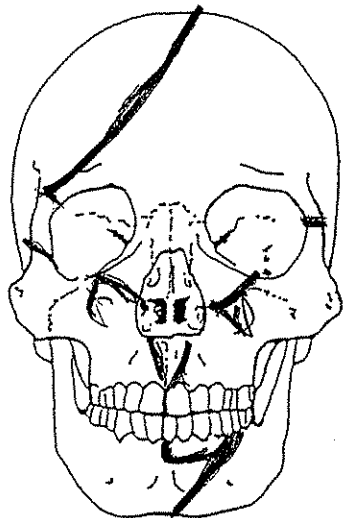
Autopsy # 135-1518

Examined By: B. Butler Date: 5/31/15

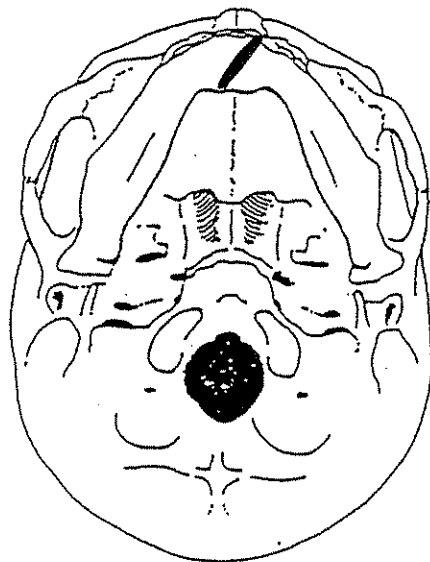
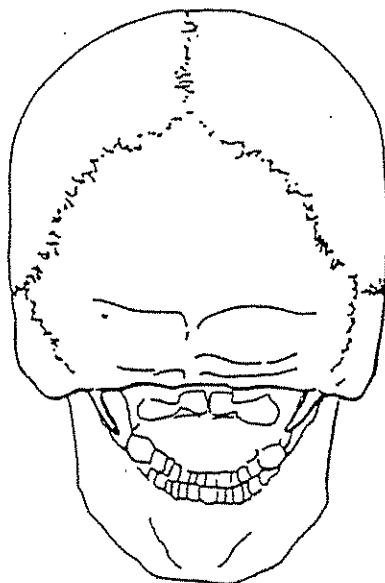
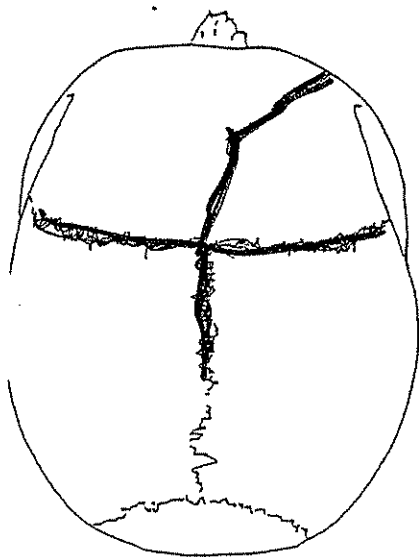
**BODY DIAGRAM:**

**SKULL (front/back, L/R, top/bottom)**

<sup>v</sup>  
<sup>u</sup>  
2 1/4" x 2 1/2"  
area of fracture



skull fractures



State of North Carolina

Office of the Chief Medical Examiner

Chapel Hill, North Carolina 27599-7580

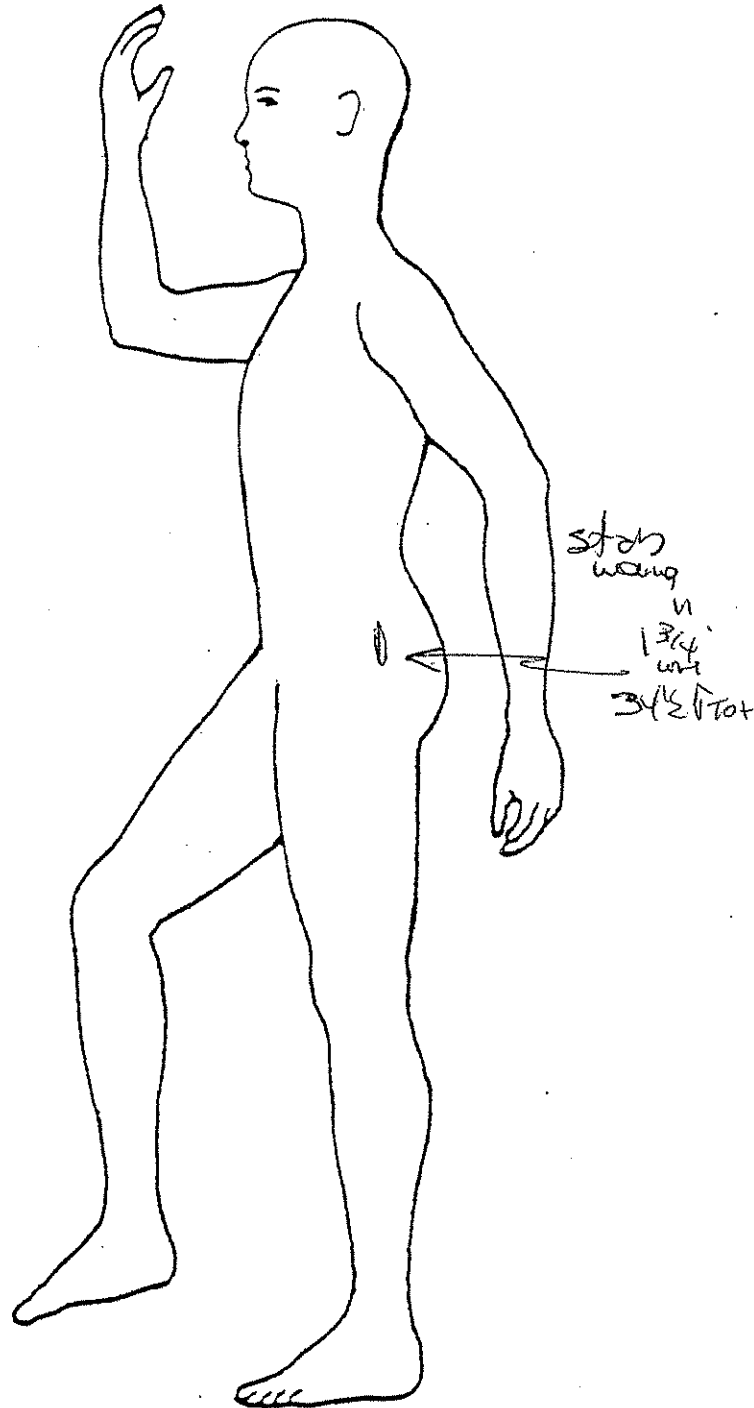
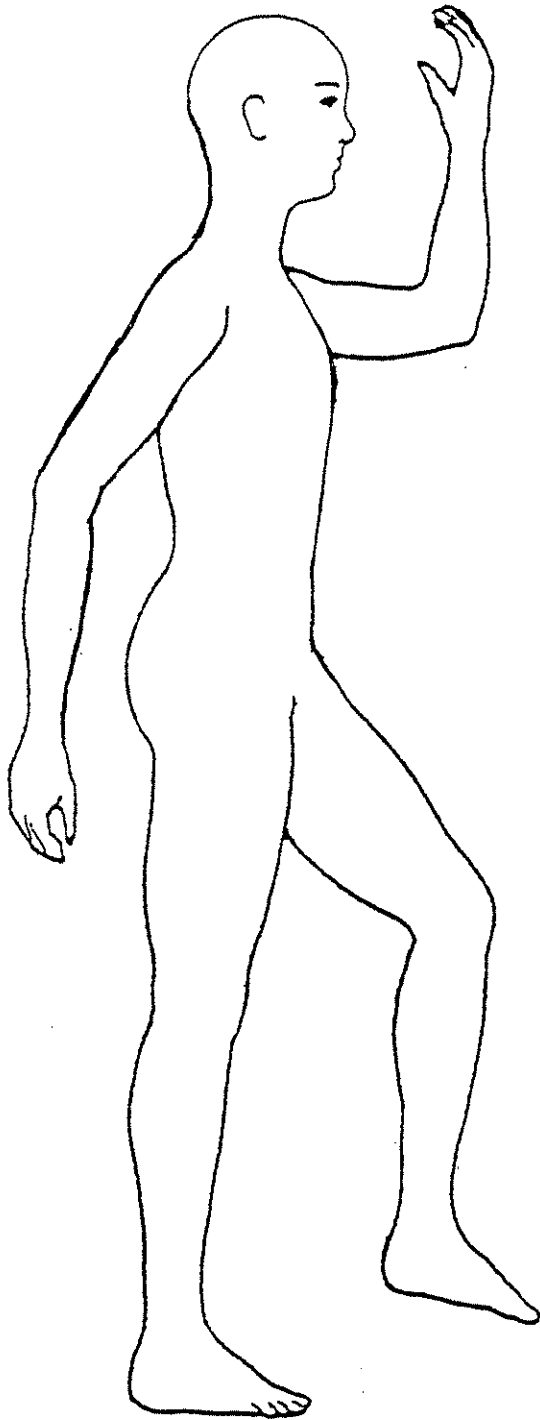
Name of Decedent: Melody Wiggins

Autopsy # BOS. 1518

Examined By: J. Burton Date: 5/2/08

**BODY DIAGRAM:**

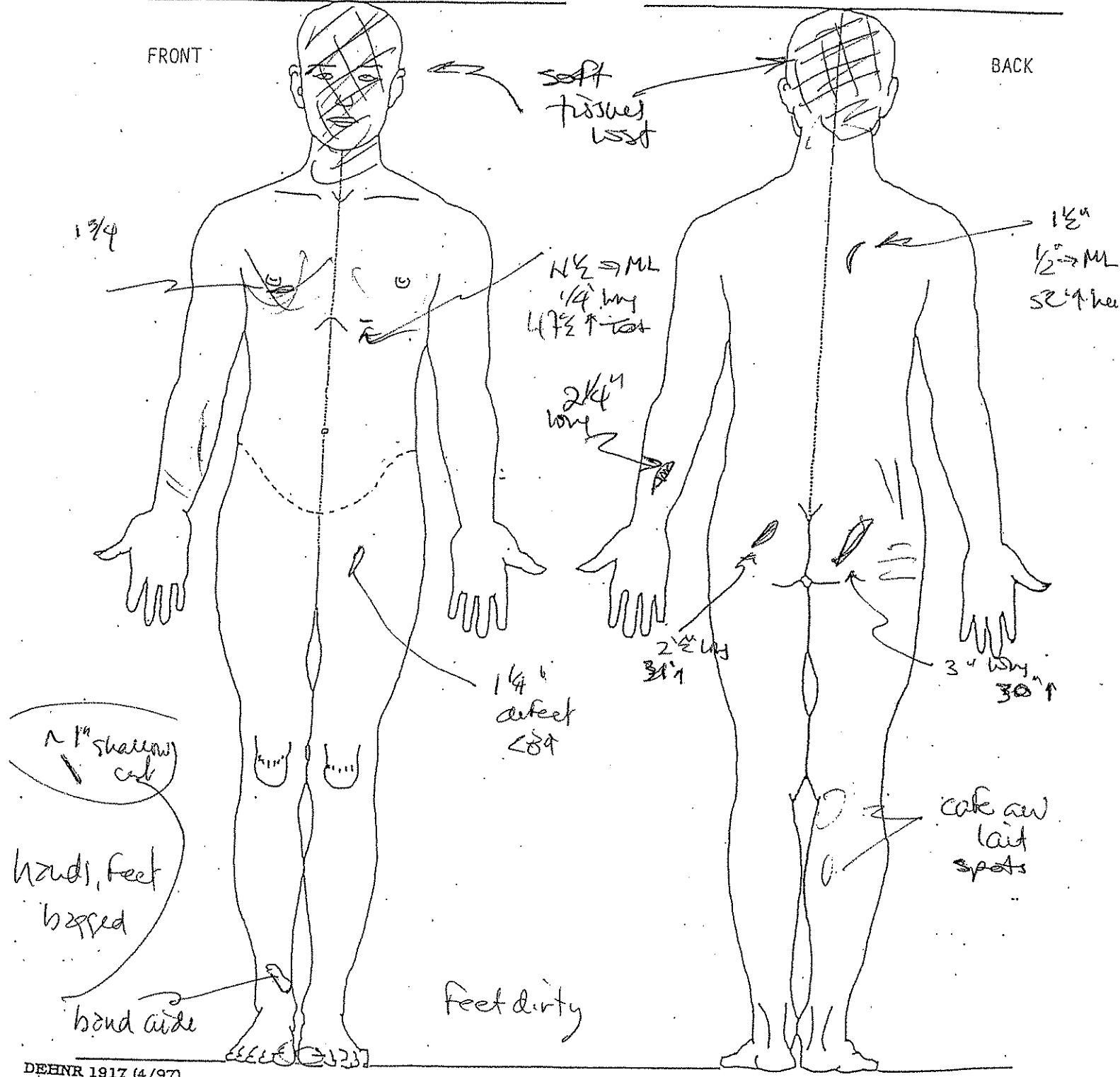
**PROFILE (Left/Right)**



BODY DIAGRAM: ADULT (Front/Back)

FRONT

BACK





State of North Carolina

Name of Decedent: Melody Wiggins

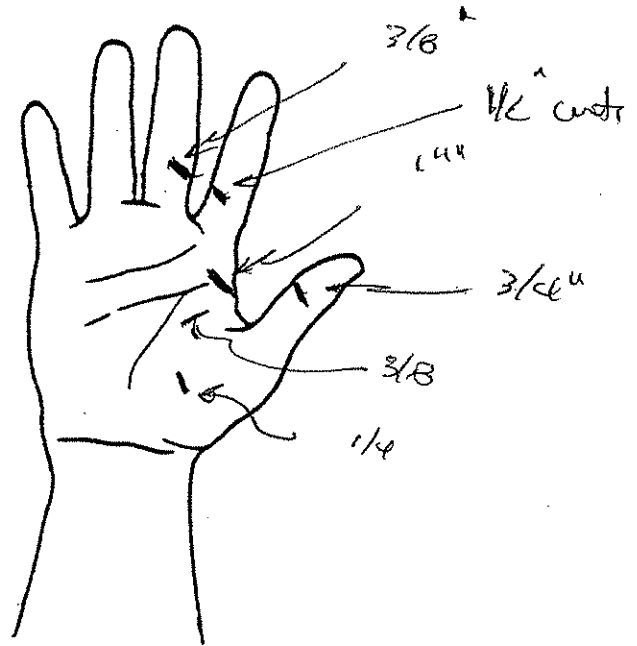
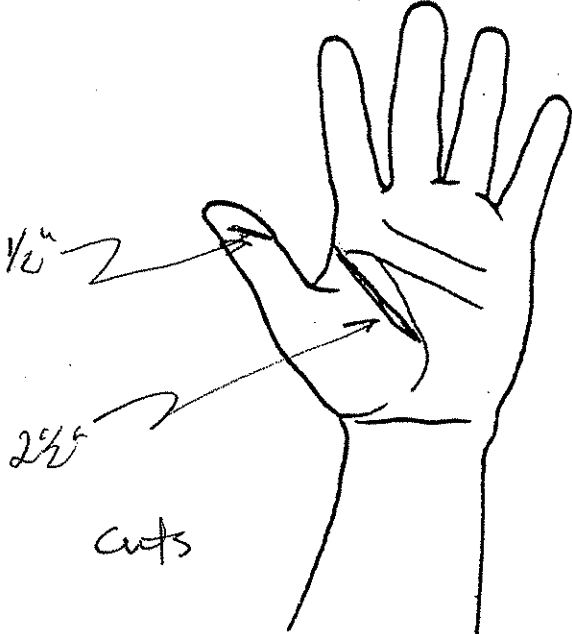
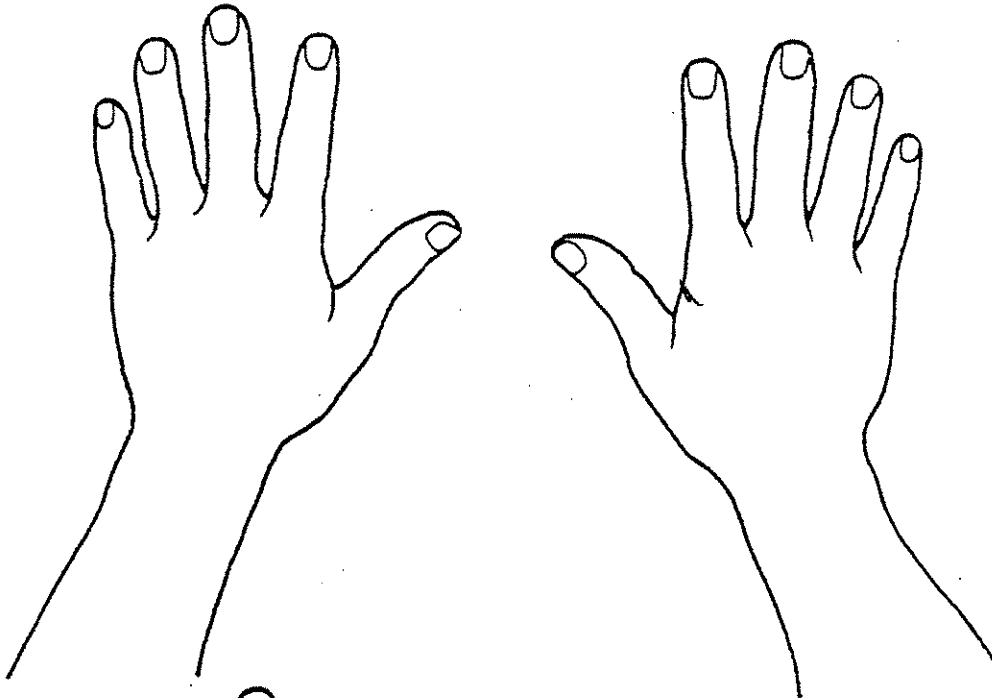
Office of the Chief Medical Examiner

Autopsy # BoS 1578

Chapel Hill, North Carolina 27599-7580

Examined By: [Signature] Date: 5/31/05

**BODY DIAGRAM: HANDS**





THE UNIVERSITY OF NORTH CAROLINA  
AT  
CHAPEL HILL

05-4631

Department of Dental Ecology JTB  
Departmental Offices (919) 966-2787

School of Dentistry  
Campus Box # 7450  
Chapel Hill, NC 27599-7450

June 3, 2005

UNC School of Medicine  
Department of Pathology: Forensic Pathology  
Re: Melody Wiggins  
DOB: 10-25-75


To Whom It May Concern:

I was asked to examine the remains presumed to be of Ms. Melody Wiggins. I manually charted the case and photographed the case also. Please see the enclosed dental records, radiographs, and my charting of the case on this day.

I am confident that the remains of this individual is that of Ms. Melody Wiggins for the following reasons:

1. The chart material states that teeth #14, 17, and 20 were extracted. This is consistent with the skeletal remains.
2. Tooth #29 appears to have deep caries on the bitewing radiographs. This tooth is missing in the skeletal remains. I would surmise that this tooth was eventually extracted due to the severity of caries.
3. Teeth #1, 2, and 3 appear supraerupted on the radiographs. This is most likely due to the individual having an unopposed dentition in this area. This supraeruption is consistent with the skeletal remains.
4. There is a diastema between teeth #8 and teeth #9 on the radiographs. The dimensions of the diastema are identical to that demonstrated by the skeletal remains.
5. The teeth missing on the lower right and left (except for tooth #17) appear to have been extracted not in the recent past as there is no evidence of remaining tooth sockets. This is consistent with the skeletal remains as there is no evidence of sockets in the posterior left and right.

There are at least 5 (above) areas of perfect congruence and I see no areas of contradiction between the records, my exam, and radiographic findings. I conclude with surety these are the remains of Ms. Melody Wiggins. If you need further assistance please feel free to contact me.

  
Allen D. Samuelson DDS  
Clinical Associate Professor  
UNC School of Dentistry  
919-966-6917  
as@unc.edu

T O X I C O L O G Y   R E P O R T

Office of the Chief Medical Examiner  
Chapel Hill, NC 27599-7580

Toxicology Folder: T200504123  
Case Folder: F200504631  
Date of Report: 06-jun-2005  
Page: 1

Case Folder  
F2005-04631

DECEDENT: Melody Wiggins

Status of Report: Approved  
Report Electronically Approved By: Justin Poklis,

\* \* \*

\*\* Comments Concerning This Report \*\*  
    No analyses requested, specimen(s) held.  
\*\* End of Comments Concerning This Report \*\*

=====

SPECIMENS received from John D. Butts on 31-may-2005

S050007057:	Liver	CONDITION: Decomposed
SOURCE:		OBTAINED: 31-may-2005

---

S050007058:	Kidney	CONDITION: Decomposed
SOURCE:		OBTAINED: 31-may-2005

---

060705 06:32

\* \* \* E N D   O F   R E P O R T   \* \* \*

B200501