



12001-09131

NORTH CAROLINA DEPARTMENT OF HEALTH AND HUMAN SERVICES  
OFFICE OF THE CHIEF MEDICAL EXAMINER  
Chapel Hill, North Carolina 27599-7580

REPORT OF INVESTIGATION BY MEDICAL EXAMINER

*BD-2384*

OCME USE ONLY
Case number
Date received
<input type="checkbox"/> Res <input type="checkbox"/> NR

DECEDENT: Kathleen A. Peterson  
First Middle Last

RESIDENCE: 1810 Cedar St. Durham NC  
Number and Street City, State

AGE: 47 SEX:  Male  Female  Unknown

RACE:  Black  Native American  Oriental  White  Unknown

HISPANIC ORIGIN:  Yes  No  Unknown

INFORMATION ABOUT OCCURRENCE

	DATE	TIME	ADDRESS OR FACILITY	COUNTY
ONSET OF INJURY OR ILLNESS				
DEATH	12-9-01	? 2:40A	1810 Cedar St. Durham	Durham
VIEW OF BODY	12-9-01	7:40A	<input checked="" type="checkbox"/> Scene of death <input type="checkbox"/> Hospital <input type="checkbox"/> Funeral home <input type="checkbox"/> Other _____ <input type="checkbox"/> Not viewed	
M.E. NOTIFIED	12-9-01	7:19A	LAW ENFORCEMENT AGENCY: <u>Durham PD</u>	
LAST KNOWN TO BE ALIVE			OFFICER: <u>AH Holland</u> TELEPHONE: <u>560-4440</u> Death occurred while in custody: <input type="checkbox"/> Yes <input checked="" type="checkbox"/> No <input type="checkbox"/> Unknown <sup>BD-2384</sup>	

AUTOPSY:  None  M.E. Authorized  Non-M.E. Autopsy facility: OCME

BLOOD SAMPLE:  Mailed  Obtained by pathologist  Reason not obtained: \_\_\_\_\_

IF CLINICAL ALCOHOL DONE, RESULT: \_\_\_\_\_ By whom: \_\_\_\_\_

PROBABLE CAUSE OF DEATH:  Pending

~~Closed Head Injury  
 DUE TO  
BFI to head  
 DUE TO  
Fell down stairs  
 DUE TO~~

OCME REVIEW		SDC
1. <u>Multiple blunt force impacts of back of the head</u>	DUE TO	<input type="checkbox"/> None
2. <u>bleeding</u>	DUE TO	<input checked="" type="checkbox"/> IAL
3. _____	DUE TO	<input type="checkbox"/> Dictated
4. _____	DUE TO	<input type="checkbox"/> COG
CONTRIBUTING CONDITIONS		
<input type="checkbox"/> Natural <input type="checkbox"/> Accident <input checked="" type="checkbox"/> Homicide <input type="checkbox"/> Suicide <input type="checkbox"/> Undetermined		
Reviewer: <u>[Signature]</u>	Date: <u>11/13/2002</u>	
<i>Information in this block supersedes that contained in space at left.</i>		

CONTRIBUTING CONDITIONS

MANNER OF DEATH:  
 Natural  Accident  Homicide  Suicide  Pending

I hereby certify that after receiving notice of the death described herein I took charge of the body and made inquiries regarding the cause of death in accordance with Article 16 of Chapter 130A of the N.C. General Statutes and the information contained herein regarding such death is true and correct to the best of my knowledge and belief.

Signature: K.S. Seelman Date: 12-9-01 Location: Durham

North Carolina Department of Health and Human Services  
Postmortem Medicolegal Examination  
Office of the Chief Medical Examiner  
Chapel Hill, NC 27599-7580  
Telephone (919) 966-2253

**REPORT OF AUTOPSY EXAMINATION**

**AUTOPSY NUMBER:** B01-2384      **CASE NUMBER:** 2001-9964  
**DECEDENT:** Kathleen Hunt Atwater Peterson  
**AGE:** 48      **RACE:** White      **SEX:** Female  
**Authorized by:** Dr. Kenneth Snell      **Received from:** Durham County  
**Date of Autopsy Examination:** 12/09/01      **Time:** 12:00 p.m.  
**Body identified by:** Transporter  
**Persons present at autopsy:** Dr. Kenneth Snell, Dr. Deborah Radisch and Mr. Kevin Gerity


**PATHOLOGICAL DIAGNOSES**

Multiple lacerations and avulsions, posterior scalp  
Multiple contusions, posterior scalp  
Subarachnoid hemorrhage, slight to moderate, bilateral parasagittal cerebral convexities  
Early acute ischemic neuronal necrosis  
Fracture with hemorrhage, superior cornu of left thyroid cartilage  
Contusions of back, posterior arms, wrists, and hands  
Multiple small abrasions and contusions, face

**CAUSE OF DEATH:** Blunt force trauma of the head

The facts stated herein are correct to the best of my knowledge and belief.

 2/18/2002  
\_\_\_\_\_  
Natalie Depcik-Smith M.D., Pathologist      Date

 2/18/2002  
\_\_\_\_\_  
Deborah L. Radisch M.D., Pathologist      Date

AUTOPSY NUMBER: B01-2384

DECEDENT: Kathleen Hunt Atwater  
Peterson

CASE NUMBER: 2001-9964

### EXTERNAL DESCRIPTION

Body condition: Intact

Length: 62 inches

Weight: 120 pounds

Body Heat: Cool

Rigor: None

Livor: Purple - posterior

Hair: Dark brown

Eyes: Gray-green

Teeth: Adequate dentition; small chip of tooth #26.

Facial hair: None

The body is that of an adult female appearing approximately the recorded age clad in a brown fleece sweatshirt and gray to white sweatpants. No decomposition changes are noted. The decedent is in good general condition with intact nail beds bilaterally. There is a nevus inferior and lateral to the left side of the umbilicus.

Evidence of medical intervention includes an EKG lead on the skin of the right lower abdomen.

### EVIDENCE OF INJURY

Hair is noted to be grasped in both the left and right hands and is collected and submitted as evidence. There is dried blood on the bottoms of the feet bilaterally with dried blood noted over the face. The nail beds are intact with crusted blood noted beneath them. No visible tissue is seen under the fingernails.

There are three contusions over the right eyelid each measuring 1/4" x 1/4". There is a right ear contusion, 1/4" x 1/4", on the right helix. There is a right neck linear vertical abrasion measuring 1/4". There are three linear horizontal abrasions, the first measuring 3/8", the next measuring 5/16", next measuring 3/16" over the left eyebrow. A linear 1/8" abrasion is noted on the right side of the nose. There is a 1/2" x 5/16" horizontal contusion over the bridge of the nose. There is a skip area and then there is a 1" x 1/2" vertical contusion over the dorsum of the nose. There is a small 3/16" x 3/16" abrasion over the lip. Inferior to the left eye are 2 small linear horizontal abrasions, each measuring 1/8" x 1/8".

**AUTOPSY NUMBER: B01-2384**

**DECEDENT: Kathleen Hunt Atwater  
Peterson**

**CASE NUMBER: 2001-9964**

**EXTERNAL:**

**HEAD:**

There are at least seven (7) distinct lacerations on the posterior scalp. Several lacerations are complex, creating avulsions with full-thickness lacerations through to the underlying skull. These will be described from right to left.

There is a tri-pronged linear laceration measuring 3" vertically, with the upper lateral prong measuring 3/4", upper medial prong 1 3/8", and lower prong 1 5/8". The greatest width of the laceration is 1".

Two and one half inches medial to the first laceration is another tri-pronged laceration with avulsion. This laceration measures 2 1/2" horizontally and 4 1/8" vertically.

At the base of the vertex closer to the right side of the scalp there are two lacerations which are horizontal over the occipital ridge. The medial laceration measures 1 1/2", and the lateral laceration measures 1", with 3/8" of scalp between the two. Immediately superior to these lacerations there is a contusion measuring 2 1/2" x 2 1/2".

Continuing onto the left posterior scalp, there is a laceration measuring 4" from vertical occiput to the posterior neck. There is an additional 2 1/2" x 1 7/8" contusion at the base of this laceration.

The previous laceration nearly intersects a vertical laceration with a deeply undermined edge, measuring 5" x 1". In addition there is a 1" flap of skin which is removed from this vertical avulsion near the left side.

There is a 1 1/8" vertical laceration which is superior and medial to the aforementioned laceration.

**TRUNK:**

On the back there is a large 3" x 3" contusion with central pressure mark over the left scapula.

**EXTREMITIES:**

On the left elbow there are 3 contusions around the elbow, one measuring 1/2" x 1/2", one measuring 1" x 1/2" and one measuring 1 1/8" x 7/8". All these contusions are more vertical than horizontal. There are two linear short abrasions over the base of the index finger of the left hand, both of which measure 1/8" x 1/8". Over the left thumb there is a contusion measuring 1/2" x 1/2". There is a left hand contusion measuring 3/8" x 3/8" over the first digit. There is a lateral left wrist contusion measuring 1/2" x 1/2". There is a left wrist contusion distal to the aforementioned contusion that measures 1/2" x 1/2". In addition there is a left hand first metacarpal 3/8" x 3/8" contusion. All blunt force

**AUTOPSY NUMBER: B01-2384**

**DECEDENT: Kathleen Hunt Atwater  
Peterson**

**CASE NUMBER: 2001-9964**

injuries are on the posterior surface of the hand and arm.

The right upper extremity shows two 1" x 1" contusions distal to the elbow approximately 2" from the elbow. There is a 1/2" x 1/2" blue contusion/abrasion which is approximately 1" proximal to the elbow. There is a lateral right wrist contusion measuring 3/8" x 3/8". There is a right hand dorsum contusion measuring 1 1/2" x 1/4" and there are two pine needles which are stuck to the dorsum of the right hand.

**INTERNAL:**

**HEAD:**

Internal examination reveals slight subarachnoid hemorrhage primarily over the left parietal and occipital lobes of the brain. No subdural hemorrhage is present. There are no contusions of the brain. There are no other abnormalities of the brain. No skull fractures are present. The neck is dissected anteriorly and posteriorly. No cervical spine (neck) fractures are present.

**NECK:**

There is a fracture with associated hemorrhage of the superior cornu of the left thyroid cartilage.

### **ADDITIONAL PROCEDURES**

**Radiographs: None**

**Microbiology: None**

**Chemistry: None**

**Evidence collected:** DNA card (aortic blood), hair from left hand, hair from right hand, head hair, clothes - sweatshirt and sweatpants, small wood splinter found in the posterior scalp hair, and blood in purple top tube received by Angela Powell of the Durham Police Department on December 9, 2001.

**Personal Effects Disposition: None**

**AUTOPSY NUMBER:** B01-2384

**DECEDENT:** Kathleen Hunt Atwater  
Peterson

**CASE NUMBER:** 2001-9964

## **INTERNAL EXAMINATION**

**Body cavities:** The serosal surfaces are smooth and glistening. There is no unusual accumulation of blood or fluid, and no adhesions are present.

**Cardiovascular system:** Heart: 240 gms. The coronary arteries have a usual right dominant distribution with thin delicate walls. No obvious atherosclerotic plaque is noted. Opening the chambers reveals normal openings and valves. The foramen ovale is not patent. The myocardium is without focal abnormality. The thoracic and abdominal aorta is unremarkable.

**Neck:** There is no hemorrhage into the strap muscles. The thyroid cartilage is intact medially. However, there is a fracture with associated hemorrhage of the superior cornu of the thyroid cartilage on the left. The thyroid gland is of the usual size and configuration. The larynx is clear.

**Respiratory system:** Lungs: Right 210 gms, Left 200 gms. The pleural surfaces are smooth and glistening. They are compressible. The major bronchi contain no foreign material. The lungs are normally formed and sectioning reveals no consolidation. The pulmonary arteries are free of premortem clot.

**Gastrointestinal tract:** The GI tract is intact throughout its length. The stomach contains approximately 400 cc's of stew-like contents with a vomitus odor. Canned mushrooms are identified. The stomach mucosa is unremarkable and not hyperemic. The small bowel, colon and appendix are intact.

**Liver:** 1150 gms. The liver capsule is smooth and intact. Sectioning reveals a homogeneous soft brown tissue. The gallbladder contains liquid green bile and the extrahepatic biliary system is patent.

**Pancreas:** Usual size, shape, and consistency.

**Spleen:** 50 gms. The splenic capsule is smooth and reddish-purple. Sectioning reveals no abnormality.

**Adrenal glands:** Unremarkable.

**Urinary system:** Kidneys: Right 90 gms, Left 90 gms. The cortical surfaces are smooth and the kidneys have usual size and shape. Sectioning reveals no abnormality. The ureters and renal arteries are intact. The bladder contains approximately 10 cc's of urine. The bladder mucosa is non-congested, non-hyperemic and unremarkable.

**Reproductive tract:** The uterus is of the usual size. There is a small right ovary corpus luteum cyst which measures 1/2" x 1/2". Sectioning reveals no abnormality.

**Musculoskeletal system:** No long bone or rib fractures are present. There is a bulging

**AUTOPSY NUMBER: B01-2384**

**DECEDENT: Kathleen Hunt Atwater  
Peterson**

**CASE NUMBER: 2001-9964**

cervical disk on the right side of the neck at C3-C4.

**Immunologic system: Unremarkable.**

**Head: Scalp:** Reflection of the scalp reveals contusions associated with full thickness lacerations as described. **Skull:** There are no skull fractures. **Brain:** 1200 gms. It is not swollen. The leptomeninges are transparent but have slight to moderate subarachnoid hemorrhage. The vessels of the circle of Willis are thin walled. The brain is formalin-fixed prior to Neuropathology Consultation. See Neuropathology Consultation.

### **MICROSCOPIC EXAMINATION**

**Heart:** There is no fibrosis or inflammation. The myocytes are not hypertrophied. A section of the right coronary artery shows less than 20% stenosis caused by atherosclerotic plaque.

**Lungs:** A section from a central area shows an airway with a small amount of blood. There is focal atelectasis in the section from the central area. A section from a peripheral area shows no inflammation or other abnormality.

**Liver:** There is slight to moderate fatty change of the hepatocytes. The portal tracts are unremarkable, without increased fibrosis or chronic inflammation.

**Kidneys:** No pathologic diagnosis.

**Ovary:** There are numerous corpora albicantia in a fibrous stroma, consistent with the decedent's age.

**Uterus:** There is a small subserosal leiomyoma with no atypical cells.

**Brain:** No contusions. Acute subarachnoid hemorrhage. See Neuropathology Consultation.

### **SUMMARY AND INTERPRETATION**

The decedent was a 48-year-old white woman who was found at bottom of a back staircase in her home. Initial indications were that the death was due to a fall down the stairs. However, due to the unusual and suspicious scene and nature of death, Dr. Kenneth Snell, Durham County Medical Examiner, assumed jurisdiction of the body and authorized an autopsy.

Autopsy examination showed multiple bruises of the arms, wrists, hands, and back with multiple small abrasions and contusions of the face. The posterior scalp showed multiple (at least 7) deep complex lacerations, some forming avulsions. No skull fractures were present, and there was a slight to moderate degree of subarachnoid hemorrhage over the brain. The brain did not show any contusions or subdural hemorrhage. There was early

**AUTOPSY NUMBER: B01-2384**

**DECEDENT: Kathleen Hunt Atwater  
Peterson**

**CASE NUMBER: 2001-9964**

acute ischemic neuronal necrosis. The neck showed no fractures. There was also a fracture with associated hemorrhage of the left superior cornu of the thyroid cartilage in the neck.

A blood ethanol (alcohol) concentration of blood obtained at the time of autopsy was 70 mg/dL (.07%), and a urine ethanol concentration was 110 mg/dL (.11%). Trace amounts of chlorpheniramine, cyclobenzaprine, and nicotine were detected in the same blood specimen. Diazepam was present in a concentration of 0.15 mg/L. No opiates or other organic bases were detected in the same blood specimen.

In my opinion, the cause of death in this case was due to severe concussive injury of the brain caused by multiple blunt force impacts of the head. Blood loss from the deep scalp lacerations may have also played a role in her death. The number, severity, locations, and orientation of these injuries are inconsistent with a fall down stairs; instead, they are indicative of multiple impacts received as a result of beating.



OFFICE OF CHIEF MEDICAL EXAMINER  
and  
DIVISION OF NEUROPATHOLOGY  
DEPARTMENT OF PATHOLOGY AND THE UNC HOSPITALS  
THE UNIVERSITY OF NORTH CAROLINA  
CHAPEL HILL, NC 27599-7525  
PHONE: (919) 966-4584

NEUROPATHOLOGY CONSULTATION

DECEDENT: Kathleen Hunt Atwater Peterson  
AUTOPSY NUMBER: B01-2384  
CASE NUMBER: 2001-9964  
AGE, RACE & SEX: 48-year-old white female  
REFERRING PHYSICIAN: Deborah L. Radisch, M.D.  
REFERRING FACILITY: Office of the Chief Medical Examiner  
DATE: 12/09/01

**CLINICAL HISTORY;** (As per initial forensic autopsy examination, 12/9/01, B01-02384). The decedent was a 48-year-old white woman who was discovered at the bottom of a back staircase in her home. Initially there were some indications that the death was due to a fall down the stairs. However, due to the unusual and suspicious scene and circumstances surrounding the nature of death, Dr. Kenneth Snell, Durham County Medical Examiner, assumed jurisdiction of the body and authorized an autopsy.

Autopsy examination showed multiple bruises of the arms, wrists, hands, and back with multiple small abrasions and contusions of the face. The posterior scalp showed multiple (at least 7) deep complex lacerations, some forming avulsions. No skull fractures were present, and there was a mild to moderate degree of subarachnoid hemorrhage over the brain. The brain did not show any contusions or subdural hemorrhage. The neck showed no fractures. There was also a fracture with associated hemorrhage of the left superior cornu of the thyroid cartilage in the neck.

A blood ethanol (alcohol) concentration of blood obtained at the time of autopsy was 70 mg/dL (.07%), and a urine ethanol concentration was 110 mg/dL (.11%). Trace amounts of chlorpheniramine, cyclobenzaprine, and nicotine were detected in the same blood specimen. Diazepam was present in a concentration of 0.15 mg/L. No opiates or other organic bases were detected in the same blood specimen.

The formalin fixed brain was submitted for Neuropathologic Consultation.

**GROSS DESCRIPTION:** This neuropathologic specimen is examined at UNC Hospital Morgue on December 17, 2001 with Dr. Deborah Radisch, Dr. Thomas Bouldin and Dr. Diane Armao. It consists of a formalin fixed brain accompanied by the dura mater. Examination of the dura mater reveals no evidence of recent or remote hemorrhage. Over the left and right cerebral convexities in the parasagittal frontal, parietal and occipital regions is a roughly oval shaped area of mild to moderate acute subarachnoid hemorrhage. The leptomeninges are otherwise unremarkable. Cerebral blood vessels are unremarkable and form a normal circle of Willis. Cranial nerves I through VIII are intact; remaining cranial nerves are difficult to assess secondary to brain removal artifact. Cerebral hemispheres are symmetric with a normal gyral pattern. There are no signs of uncus or tonsillar herniation. The cerebellum and brainstem show a normal configuration. Intact dura mater covers the cervical, thoracic and lumbar portions of the spinal cord. A small 0.4 cm discrete focus of acute epidural hemorrhage is noted at the rostral extremity (cervical aspect) of the spinal cord; this change is consistent with focal disruption secondary to spinal cord removal at autopsy. Spinal leptomeninges are unremarkable. The spinal cord shows no lesions.

The cerebrum, cerebellum and brainstem are sectioned. The cerebral hemispheric gray and white matter are intact. There is no evidence of contusional injury. The ventricles are normally formed and of normal size. Central white matter, corpus callosum and deep gray nuclei of the thalamus, hypothalamus and basal ganglia are without gross abnormality. Choroid plexuses are unremarkable. Sections of cerebellum and brainstem show no abnormality. Serial transverse sections of spinal cord are unremarkable.

AUTOPSY NUMBER: B01-2384

DECEDENT: Kathleen Hunt Atwater Peterson


CASE NUMBER: 2001-9964


**MICROSCOPIC DESCRIPTION:** All sections are stained by the hematoxylin and eosin method. Sections of cerebellum reveal rare red neurons in the Purkinje cell layer. The red neurons are consistent with early acute ischemic necrosis. The red neurons display pyknotic nuclei and bright pink cytoplasm. Similar, but less well developed changes of acute neuronal injury are identified in rare neurons within the cerebral neocortex. In one area these acutely injured neurons show a laminar distribution in the cerebral neocortex. Sections from parasagittal cerebral cortex show a mild to moderate degree of acute subarachnoid hemorrhage. Scattered cells containing brown pigment within areas of acute hemorrhage are iron-negative with special stains. There is no evidence of contusional injury. Sections of corpus callosum, deep white matter and pons are histologically unremarkable.

**DIAGNOSIS:**

- I. Acute neuronal injury, cerebellum and cerebral neocortex, consistent with early acute ischemic neuronal necrosis (see comment)
- II. Mild to moderate acute subarachnoid hemorrhage, right and left parasagittal cerebral convexities, consistent with head trauma

**COMMENT:** In this case, rare red neurons, consistent with acute ischemic neuronal necrosis, are present in cerebrum and cerebellum. These findings are consistent with the decedent having a significant episode of widespread brain ischemia at least a few hours prior to death.

  
Diane Armao, MD  
Neuropathology

  
Thomas W. Bouldin, MD  
Neuropathologist

/ocme/path/neuro/2001/B01-2384

State of North Carolina

Name of Decedent: Kathleen A. Peterson

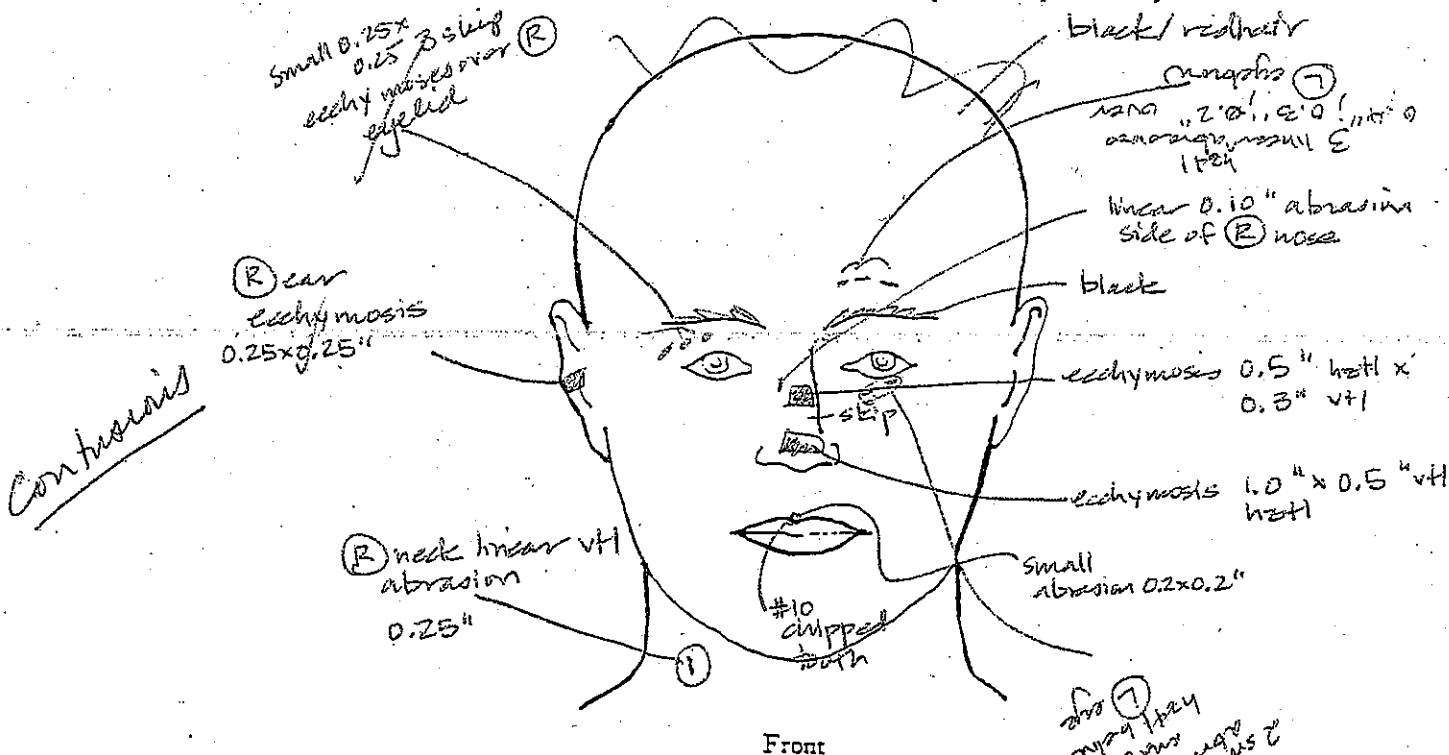
Office of the Chief Medical Examiner

Autopsy # B01-2384

Chapel Hill, North Carolina 27599-7580

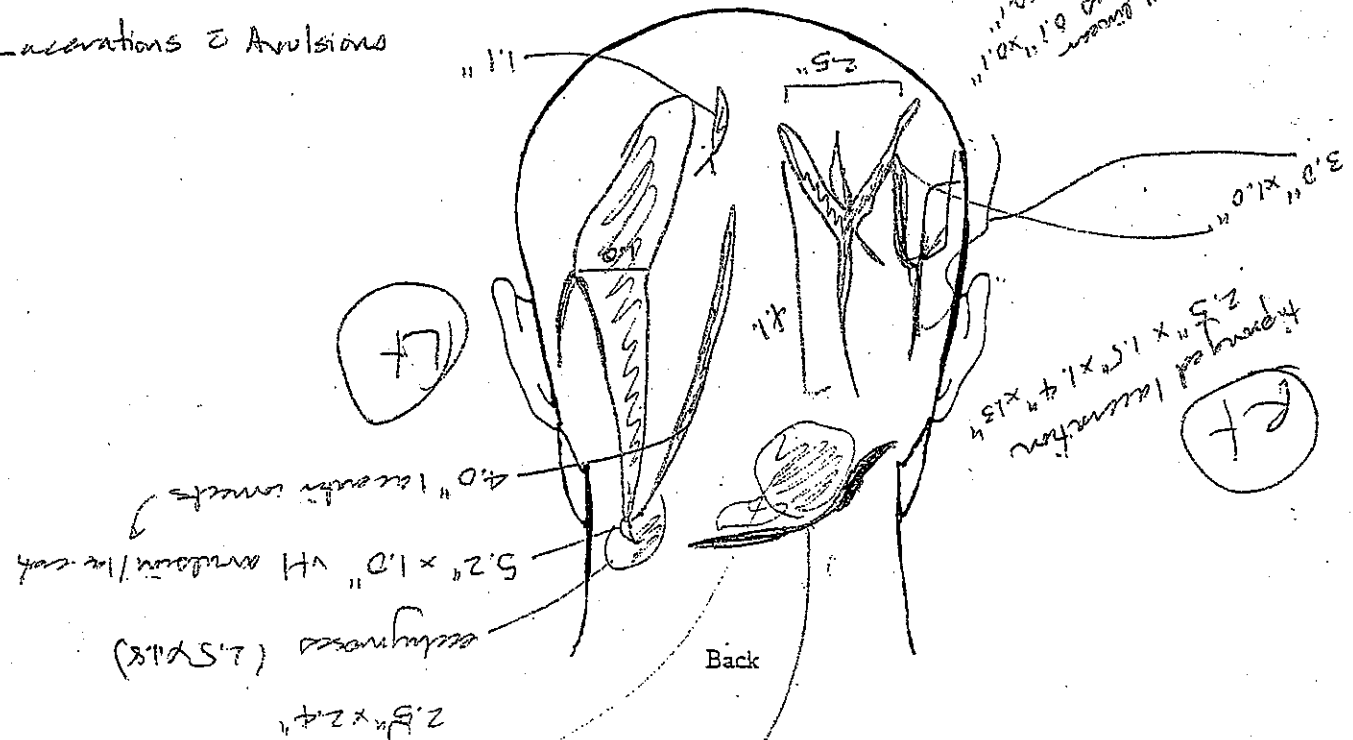
Examined By: Depait Smith Date: 12/07/01  
Radich / A

BODY DIAGRAM: HEAD (front/back)



Front

Lacerations & Avulsions



Back

State of North Carolina

Name of Decedent: Kathleen A. Peterson

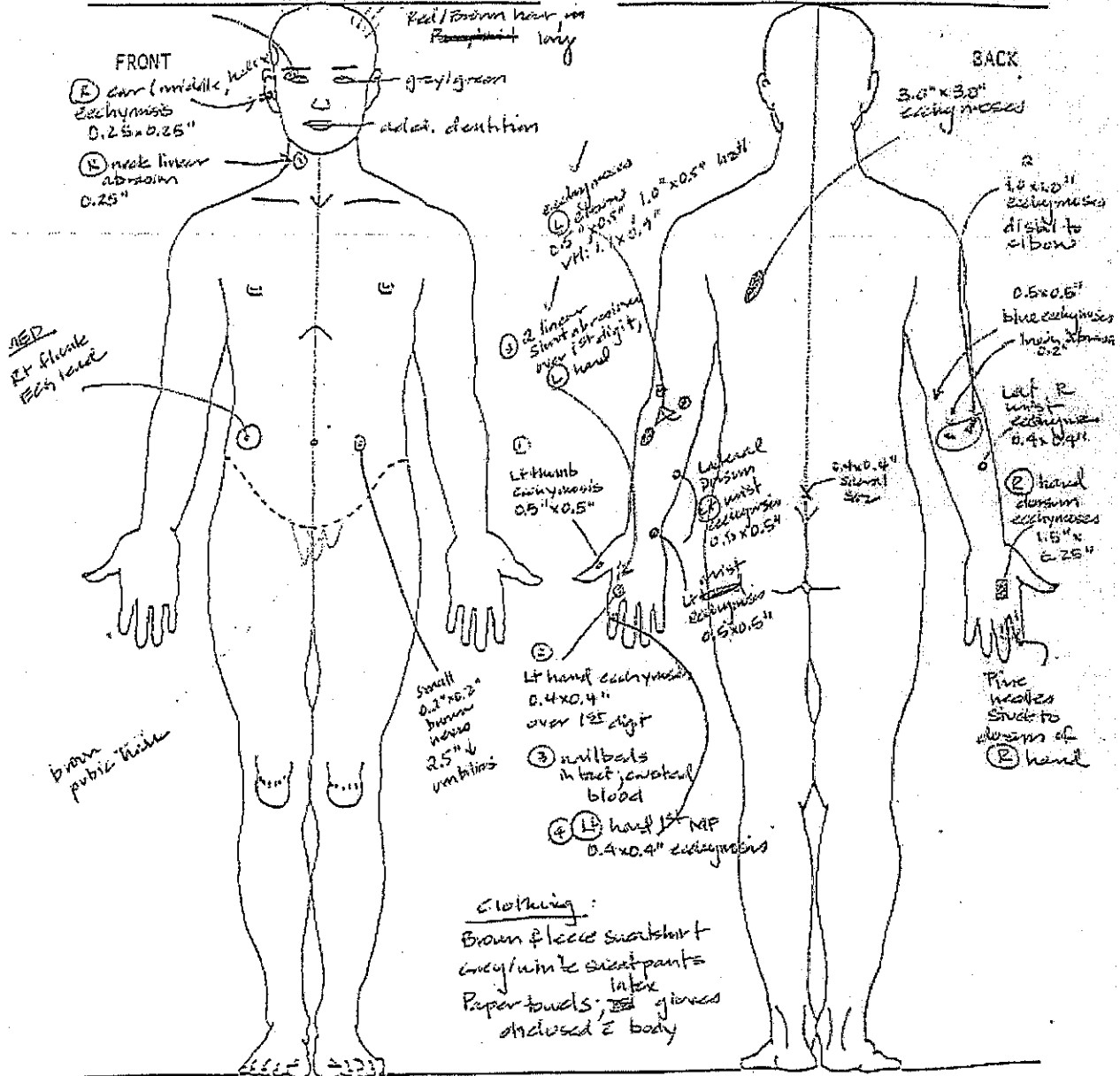
Office of the Chief Medical Examiner

Autopsy # B01-2334

Chapel Hill, North Carolina 27599-7580

Examined By: Depink-Smith Date: 12/10/10  
Snell/Barlock

**BODY DIAGRAM: ADULT (Front/Back)**



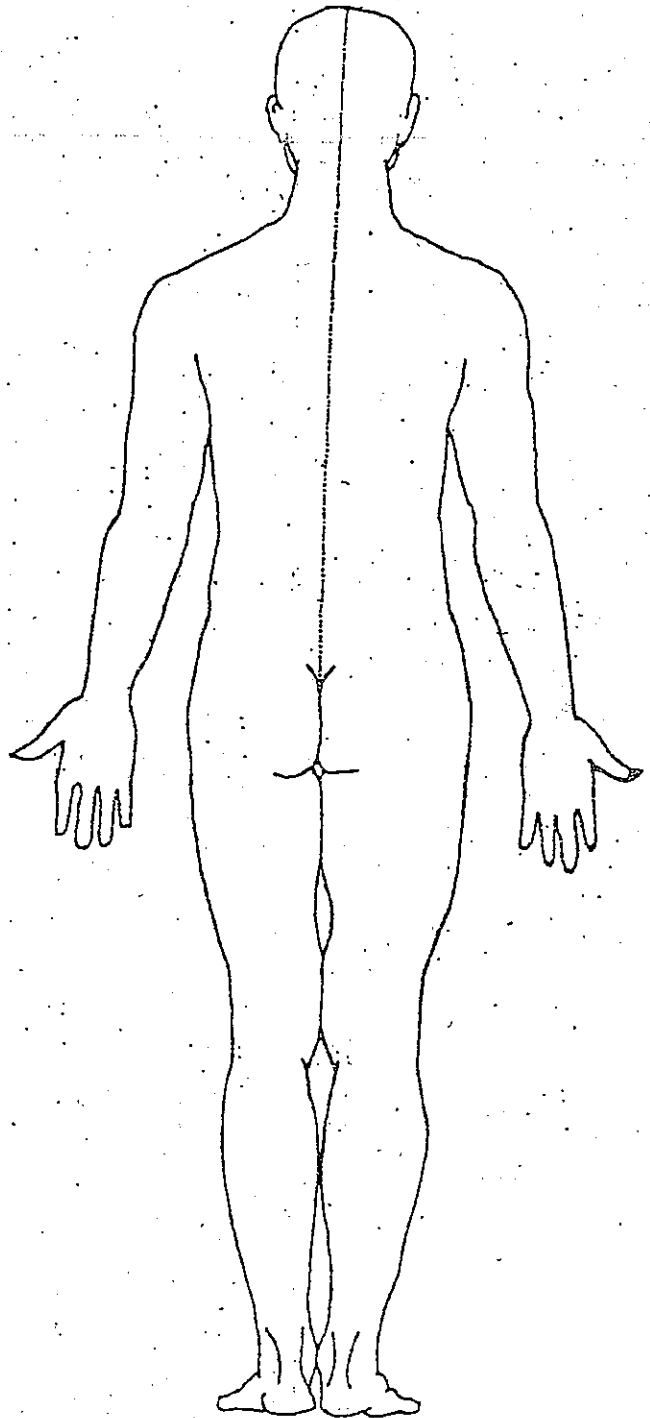
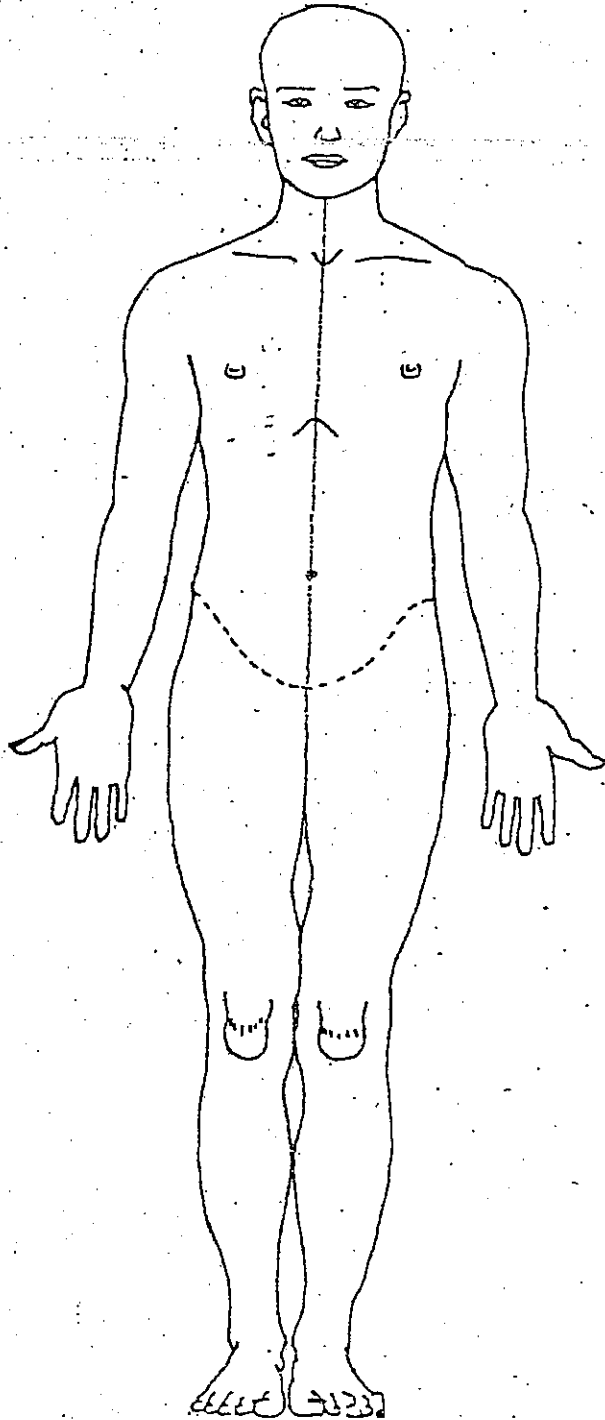
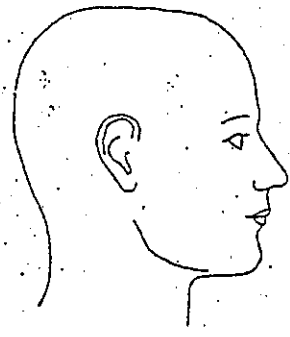
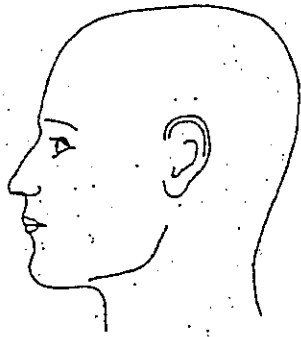
DHHS 1917 (4/97)  
Medical Examiner

This form may be photocopied.

Dried blood on all clothes; Feet bottoms (E)  
Dried blood over face

BODY DIAGRAMS

*for autopsy*



Indicate nature and location of wounds and other lesions (scars, tattoos, medical therapy, etc.) on these diagrams.