



12009-01793

NORTH CAROLINA DEPARTMENT OF HEALTH AND HUMAN SERVICES
OFFICE OF THE CHIEF MEDICAL EXAMINER
Chapel Hill, North Carolina 27599-7580

REPORT OF INVESTIGATION BY MEDICAL EXAMINER

JB

OCME USE ONLY

09-1992

Case number
FEB 23 2009

Date received
 Res NR

DECEDENT: Mayela Orduna
First Middle Last Suffix

RESIDENCE: _____
Number and Street City, State County

AGE: 18 SEX: Male Female Unknown

RACE: Black Native American Oriental White Unknown

HISPANIC ORIGIN: Yes No Unknown

INFORMATION ABOUT OCCURRENCE

| | DATE | TIME | ADDRESS OR FACILITY | COUNTY |
|----------------------------|---------|-------|---|--------|
| ONSET OF INJURY OR ILLNESS | 2/17/09 | ~3 AM | Aversboro Rd - Garner | Wake |
| DEATH | " | 2335 | Wake Med | " |
| VIEW OF BODY | 2/19/09 | 1120 | <input type="checkbox"/> Scene of death <input type="checkbox"/> Hospital <input type="checkbox"/> Funeral home <input checked="" type="checkbox"/> Other <u>Scene</u> <input type="checkbox"/> Not viewed | |
| M.E. NOTIFIED | | | LAW ENFORCEMENT AGENCY: <u>Garner PD</u> | |
| LAST KNOWN TO BE ALIVE | | | OFFICER: _____ TELEPHONE: _____ Death occurred while in custody: <input type="checkbox"/> Yes <input checked="" type="checkbox"/> No <input type="checkbox"/> Unknown | |

AUTOPSY: None M.E. Authorized Non-M.E. Autopsy facility: _____

BLOOD SAMPLE: Mailed Obtained by pathologist Reason not obtained:

IF CLINICAL ALCOHOL DONE, RESULT: 279 mg/dL By whom: Wake Med

PROBABLE CAUSE OF DEATH: Pending

1. Blunt force head trauma

DUE TO _____

2. _____

DUE TO _____

3. _____

DUE TO _____

4. _____

OCME REVIEW

1. Blunt force head trauma

DUE TO _____

2. Jumped or fell from moving vehicle

DUE TO _____

3. _____

DUE TO _____

4. _____

alcohol

CONTRIBUTING CONDITIONS

Natural Accident Homicide Suicide Undetermined

Reviewer: JB Date: 3/17/09

Information in this block supersedes that contained in space at left.

SDC

None

AL

Dictated

COG

CONTRIBUTING CONDITIONS

MANNER OF DEATH:

Natural Accident Homicide Suicide Pending

I hereby certify that after receiving notice of the death described herein I took charge of the body and made inquiries regarding the cause of death in accordance with Article 16 of Chapter 130A of the N.C. General Statutes and the information contained herein regarding such death is true and correct to the best of my knowledge and belief.

Signature of Medical Examiner: [Signature] Date: 2/19/09 County of Appointment: Wake M.E. Number: _____

NARRATIVE SUMMARY OF CIRCUMSTANCES SURROUNDING DEATH

Apparently at party in apt where she was staying with boyfriend. Drinking, got into argument with another female. Boyfriend took her away to cool down, drove off in car. At some point he claimed she left car while he was driving at 30 mph. He did not stop but drove back to apt. At some point told others that she had left vehicle and they went back to look for her found in ditch off road - 911 called but bf did not stay at scene. Taken to Wake Med where head trauma found - pronounced brain dead ~ 20 hours after admission. kept on support for organ donation. Remains brought to OCMJE-2/19/09. Clinical alcohol at Wake Med was 279 mg/dL.

PURPOSE: To document the findings of a medical examiner investigation. When completed, this form constitutes a report to the Chief Medical Examiner as required by G.S. 130A-385(a).

PREPARATION: The investigating medical examiner completes all appropriate information, and signs the certification statement on the front of the form.

DISTRIBUTION: Mail original copy to the Office of the Chief Medical Examiner, Chapel Hill, NC 27599-7580.

DISPOSITION: This form is maintained by the Chief Medical Examiner in accordance with the current records disposition schedule published by the N.C. Division of Archives and History.

COPIES: Additional copies may be ordered from the Office of the Chief Medical Examiner, Chapel Hill, NC 27599-7580.

MEDICAL HISTORY

- Alcoholism, Diabetes, IV drug abuse, Ischemic heart disease, Smoking, Seizure disorder, Cancer, Hypertension, Depression, HIV/AIDS, Other, Attending Physician, City

MEANS OF DEATH

- VEHICLE: Type of vehicle associated with this decedent: Passenger car, Pickup truck, Truck--more than 2 axles, Motorcycle, Bicycle, Farm vehicle, ATV, Moped, Other, Position: Driver, Passenger, Pedestrian, Unknown, Devices: Seat restraints, Air bag, Helmet, Child restraint, None, Unknown, Number of vehicles involved 1, GUN: Rifle--Caliber, Handgun--Caliber, Shotgun--Gauge, Other, INSTRUMENT: Blunt, Sharp, Description, TOXIC AGENT(S) SUSPECTED: Alcohol, Others, DROWNING: Pond, Lake or river, Ocean, Pool, Bathtub, Other, Life preserver: Yes, No, Unknown, Able to swim: Yes, No, Unknown, Activity, FIRE: Suspected cause, Smoke detector: Yes, No, Unknown, FALL: From, to, Approximate distance, feet

ACTIVITY OF DECEDENT AND PREMISES

FATAL INJURY OR ILLNESS: Activity riding in car, Type of place, Specific location

Fatal injury or illness occurred on a job: Yes, No, Unknown, If yes, was employment: Primary job, Secondary, Volunteer work, Unknown, Name of this employing firm or agency, Type of business or industry, Decedent's occupation

DEATH: Type of place hospital, Specific location

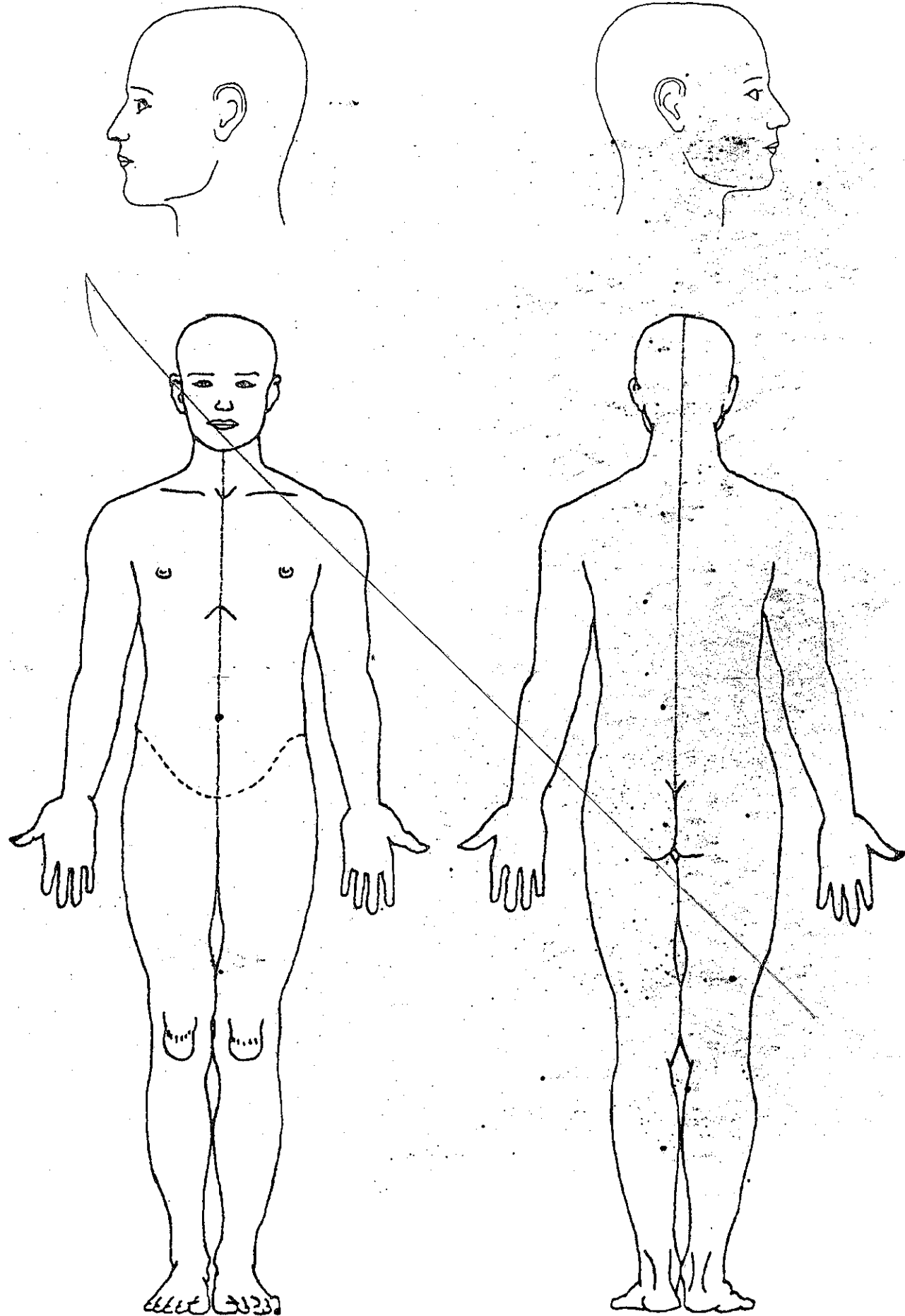
Examples: Activity: Running, lifting hay bales, eating, typing letter, driving commercial truck, sleeping, bathing, watching television, fighting, etc. Type of place: House, apartment, trailer, school, jail, bar or tavern, hotel, restaurant, store, street, hospital, farm, highway, factory, etc. Specific location: Bathroom, assembly line, kitchen, front yard, office, parking lot, emergency room, roadside, ambulance, car, etc. On a job: Any activity that is income generating regardless of age of decedent including farming or part time work; also include non-income generating volunteer or charity work.

DESCRIPTION OF BODY

- CONDITION: Intact, Decomposition, Skeletonized, Embalmed, Charred, Prolonged immersion, Exhumed, RIGOR: None, 1+, 2+, 3+, LIVOR: None, Anterior, Posterior, Lateral, HEIGHT: inches, Estimate, WEIGHT: pounds, Estimate, BODY TEMPERATURE: Warm, Cool, Cold, HAIR: Color, Beard, Mustache, EYES: Color, Abnormalities, TEETH: Upper, Lower, Natural, Dentures, Abnormalities, CLOTHING: Not clothed, VALUABLES: No valuables

See autopsy
report

BODY DIAGRAMS



Indicate nature and location of wounds and other lesions (scars, tattoos, medical therapy, etc.) on these diagrams.

Office of the Chief Medical Examiner

CB # 7580 Chapel Hill, NC 27599-7580
Telephone 9199662253

REPORT OF AUTOPSY EXAMINATION

DECEDENT

Document Identifier B200901028
Autopsy Type ME Autopsy
Name Mayela Orduna
Age 18 yrs
Race Unknown
Sex F

AUTHORIZATION

Authorized By John D. Butts MD **Received From** Wake

ENVIRONMENT

Date of Exam 02/19/2009 **Time of Exam** 11:30
Autopsy Facility Office of the Chief Medical Examiner **Persons Present** Ms. Molly Hupp, Mr. Bill Holloman

CERTIFICATION

Cause of Death
Blunt force head trauma

The facts stated herein are correct to the best of my knowledge and belief.

Digitally signed by
John D. Butts MD 17 March 2009 13:10

DIAGNOSES

Blunt force head trauma with laceration and contusion of posterior scalp, fracture of right occipital bone, left subdural hematoma, bilateral frontal and temporal lobe contusions, left greater than right
Abrasions of back
Declaration of brain death with harvest of organs of chest and abdomen

IDENTIFICATION

Body Identified By
Papers/ID Tag

EXTERNAL DESCRIPTION

Length 62 inches
Weight 99 pounds
Body Condition Intact
Rigor Minimal
Livor Posterior, slight
Hair Dark, long
Eyes Brown, 6 mm pupils
Teeth Natural

These are the remains of a small, slender but normally developed appearing female. When she is received there is evidence of multiple therapeutic and organ donation procedures present. An endotracheal tube is present in the mouth, a nasogastric tube in the left nares. An IV is present in the left subclavicular region. IVs are also noted on the right wrist and back of the left forearm. A urethral catheter is in place attached to a collection bag. An oxygen sensor is noted on the right index finger. EKG electrodes are present. There is a blood pressure cuff around the right upper arm and pressure cuffs are present around both lower legs. ID tags are present on each wrist.

There is a sutured donor incision extending from the sternal notch to the pubic symphysis in the midline and a horizontal incision across both upper abdominal quadrants.

Two tattoos are noted on the body. There is a blue and green butterfly on the right lower abdominal quadrant and a heart on the back of the left shoulder. There is reddish-purple polish on the fingernails and some residual reddish polish on the toenails.

INJURIES

External signs of injury include an approximately 6.5 x 4" area of roughly L-shaped abrasion both shallow and deeper on the left superior buttock/small of back region extending towards the midline.

On the superior right shoulder is a 4 x 2.5" area of abrasion.

On the left back extending from near the midline towards the superior left shoulder is a 3 x 1.5" abrasion and then across the top of the left shoulder an approximately 3 x 3" area of abrasion.

There are areas of bruising in the subclavicular areas bilaterally, more so on the right than the left that may represent artifacts. There is an approximate 1" area of bruising on the anterior left lower leg and there is bruising and slight swelling of the lateral surface of the left ankle. There are scattered bruises associated with needle marks on the forearms, backs of the wrists and hands.

Bruising is noted behind each ear, more on the right than the left and there are some fine abrasions of the right cheek. In the midline posterior supraoccipital region is an area of abrasion/bruising approximately 2-3" in overall diameter within which are two lacerations. The more superior one is slightly transverse and crescentic measuring 0.7" in length. The more inferior one is roughly horizontal and 1" in length.

Internally there is an extensive area of undermining beneath these lacerations within the scalp itself and blood clots are present. No foreign materials are noted. Internally there is extensive subscalpular and subgaleal hemorrhaging in this area. There is some slight bruising in the temporal regions. There is a long linear fracture within the right occipital bone. It extends from the petrous portion of the right temporal bone backwards moving slightly towards the midline until it reaches the lambdoid suture. A short arm extends medially approximately a 1/2" just prior to the suture. There is no significant epidural clot in this area. There is jelly-like, approximately 40-60 gm, clot located over the left cerebral hemisphere. Over the convexities there is subarachnoid hemorrhage of a mild degree on the left and some on the right as well. There is considerable adherent clot on the anterior portion of the left frontal lobe and relatively thick subarachnoid hemorrhage as well. The undersurface of the brain shows prominent contusions of the tip of the left temporal lobe and some more posteriorly. There is a lesser degree of hemorrhage on the tip of the right temporal lobe. There are contusions noted on the undersurface of both frontal lobes, slightly moreso on the left. A few small contusions are noted scattered on the surface of the left parietal and occipital lobes. The contusions in the left frontal and temporal lobes extend into the parenchyma approxiamtely 4-5 mm.

Other injuries present are related to therapeutic or harvesting procedures.

DISPOSITION OF CLOTHING AND PERSONAL EFFECTS

The following items are released with the body

None

The following items are preserved as evidence

None

PROCEDURES

Radiographs

None

Microbiology

None

Chemistry

None

Special Evidence Collection

Blood stain sample card prepared from residual blood in the aorta and that and a scalp hair sample turned over to Garner PD.

INTERNAL EXAMINATION

Body Cavities

The pleural, pericardial and peritoneal cavities have been opened secondary to organ procurement. The only organs remaining in place are the pelvic ones. There is some loose fluid and the remaining organs as noted are loose within the abdominal and chest cavities.

Cardiovascular System

The heart is completely absent as is the ascending aorta. A portion of the aortic arch and the descending aorta to approximately the diaphragm are still present and attached to the vertebral column. They show only minimal atherosclerosis.

Respiratory System

Both lungs are absent as is the distal trachea and bronchi. The proximal trachea is present and has been stapled distally. There is some slight sublaryngeal hemorrhage consistent with intubation. The hyoid bone and thyroid cartilages are intact. There is no swelling of the larynx. There is some slight edema of the aryepiglottic folds.

Gastrointestinal System

The stomach is present attached to the esophagus. The distal portion of the stomach has been interrupted and is fastened with staples just presumably proximal to the pylorus. The stomach contains some thick greenish fluid and some purplish soft linear material that easily fragments. The duodenum is absent. The remainder of the small bowel is present as well as the large bowel. The appendix is in place. Formed stool is present in the large bowel.

Liver

The liver is absent.

Spleen

The spleen is absent.

Pancreas

The pancreas is absent.

Urinary

Both kidneys are absent. The bladder is present and empty.

Reproductive

Uterus, tubes and ovaries are present. The uterine cavity contains thin endometrium. The uterus is of normal size. The cervix contains some bloody mucous. The vagina appears unremarkable.

Endocrine

The thyroid gland appears small but otherwise unremarkable.

The adrenals are absent.

Neurologic

Brain Weight 1280 grams

The meninges show hemorrhage as described. The vasculature at the base of the brain shows no obvious atherosclerosis. Injury is present as noted. The brain is markedly softened and friable, particularly the brainstem. Multiple coronal sections show injuries as described but no obvious pre-existing abnormalities.

Skin

Abnormalities as noted.

Immunologic System

No lymphadenopathy identified.

Musculoskeletal System

Injuries present as noted.

MICROSCOPIC EXAMINATION

Neurologic

Sections of cerebrum, cerebellum and brainstem show prominent eosinophilia of neurons and pericellular vacuolation. Areas of interstitial and subarachnoid hemorrhage are noted.

SUMMARY AND INTERPRETATION

This was an 18-year-old woman whose body was apparently found by the side of a road in Wake County on the 17th of February. Her identity was initially unknown. She was brought to Wake Medical Center where she was noted to have a laceration on the back of her head, a skull fracture, as well as intracerebral trauma. She was declared brain dead but maintained on life support for some time for the purpose of organ donation. Prior to that she was identified and a history obtained that she had allegedly exited a passenger car moving at approximately 30 MPH near the site of where her body was found. An ethanol concentration of 279 mg/dl was found in a sample of blood drawn a short time after admission to the hospital.

Autopsy examination revealed evidence of prior organ donation. Virtually all the organs of the chest and abdomen were absent. Clinical work-up and reports of the donor team indicate they were in a normal state of health without evidence of trauma or other pathology. Injuries present on the body included abrasions of both shoulder regions and the left lower back. There was evidence of a blunt force impact to the central back of the head with laceration of the scalp, fracture of the right occipital skull and brain injuries. The latter consisted of a left subdural hematoma and contusions of the undersurfaces of the frontal and temporal lobes bilaterally.

The overall configuration of the injuries to the head are consistent with those that would have been incurred had the back of her moving head struck a hard surface. These injuries in addition to the abrasions of her back could have been incurred by her striking the ground or pavement after exiting a moving vehicle. In my opinion, her death was the result of this head trauma.

DIAGRAMS

1. Adult (front/back)
2. Head (left/right)
3. Head (front/back)
4. Skull & scalp (top)
5. Brain, superior, inferior and lateral views

State of North Carolina

Name of Decedent: Mayela Ordana

Office of the Chief Medical Examiner

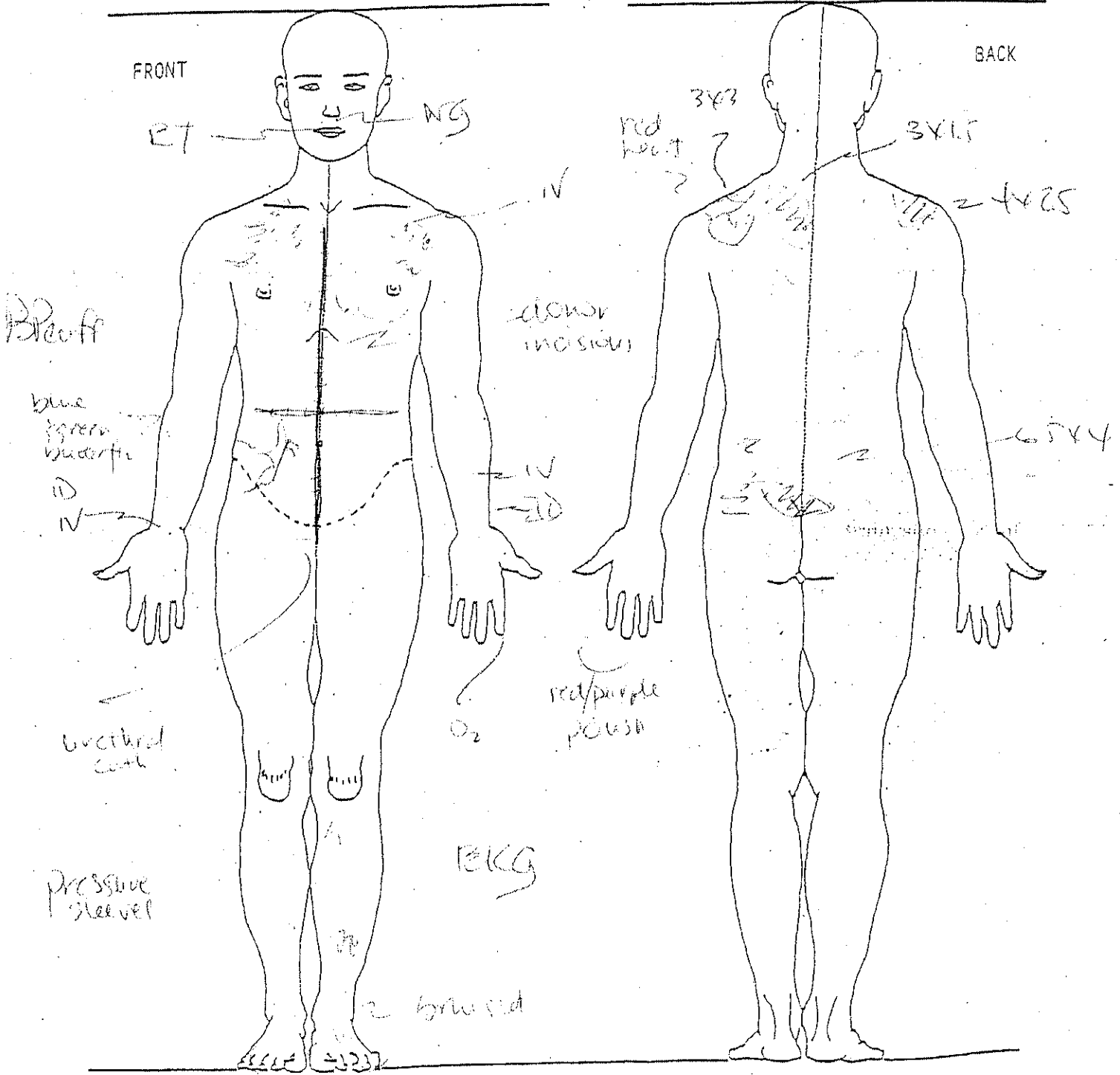
Autopsy # BEG 1028

Chapel Hill, North Carolina 27599-7580

Examined By: JOB

Date: 2/19/09

BODY DIAGRAM: ADULT (Front/Back)



DEENR 1917 (4/97)
Medical Examiner

This form may be photocopied.

PAGE ___ OF ___

State of North Carolina

Name of Decedent:

Maryann Crutcher

Office of the Chief Medical Examiner

Autopsy #

1229-1000

Chapel Hill, North Carolina 27599-7580

Examined By:

DB

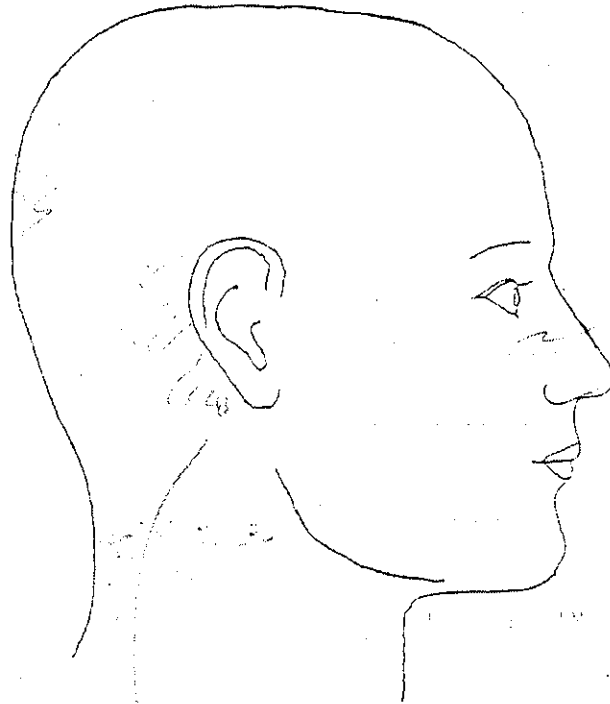
Date:

2/15/69

BODY DIAGRAM: HEAD (left/right)

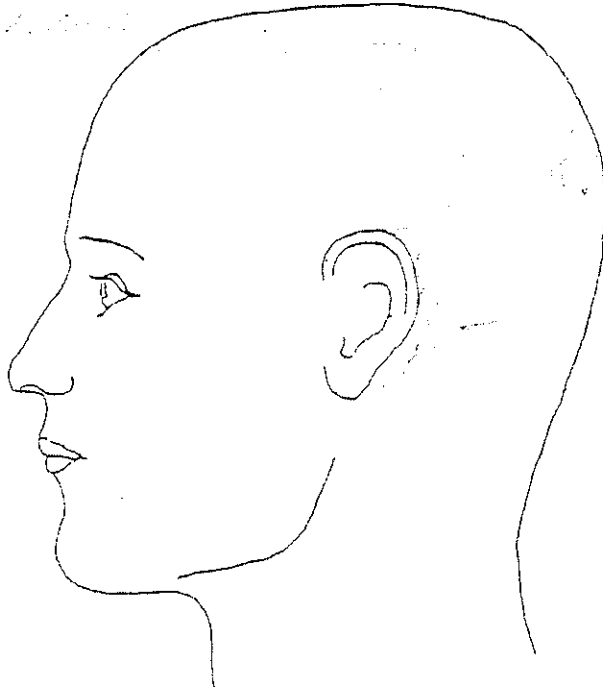
Right

abrasions
laceration
bruising



a few
small
scabs

Left



postauricular
bruising

DEHNR 1920 (4/97)
Medical Examiner

This form may be photocopied.

PAGE ___ OF ___

State of North Carolina

Name of Decedent: Marylou Craddock

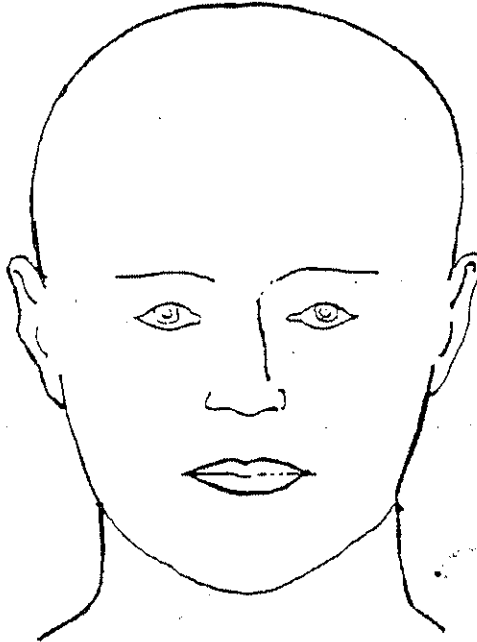
Office of the Chief Medical Examiner

Autopsy # 59 1018

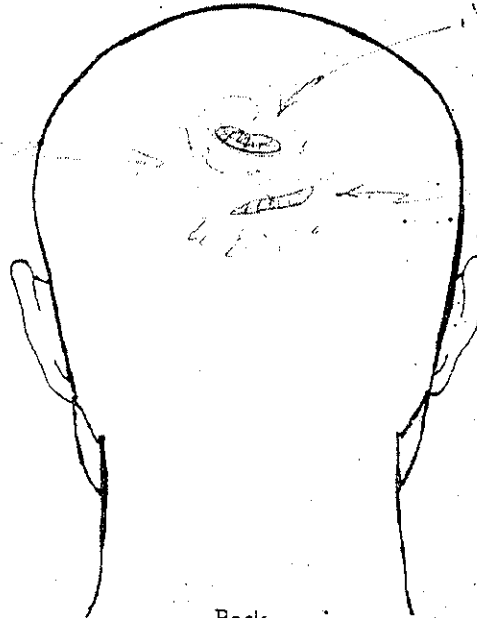
Chapel Hill, North Carolina 27599-7580

Examined By: JMS Date: 4/9/89

BODY DIAGRAM: HEAD (front/back)



Front



Back

State of North Carolina

Name of Decedent: Mayela Cordero

Office of the Chief Medical Examiner

Autopsy # B09 1526

Chapel Hill, North Carolina 27599-7580

Examined By: T.B. Date: 2/19/99


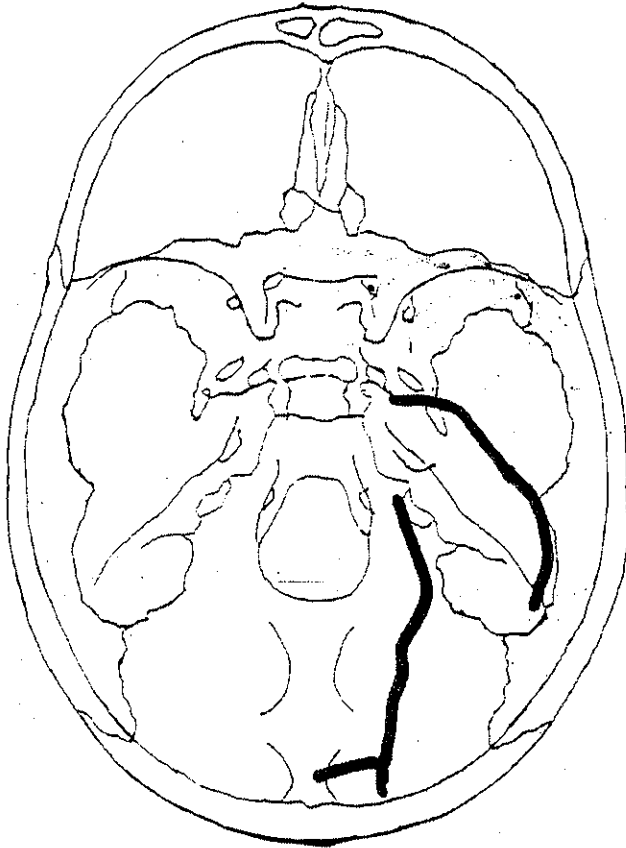
BODY DIAGRAM: SKULL & SCALP (top)

FRONT

LEFT

RIGHT

BACK



DHHS 1922 (4/97)
Medical Examiner

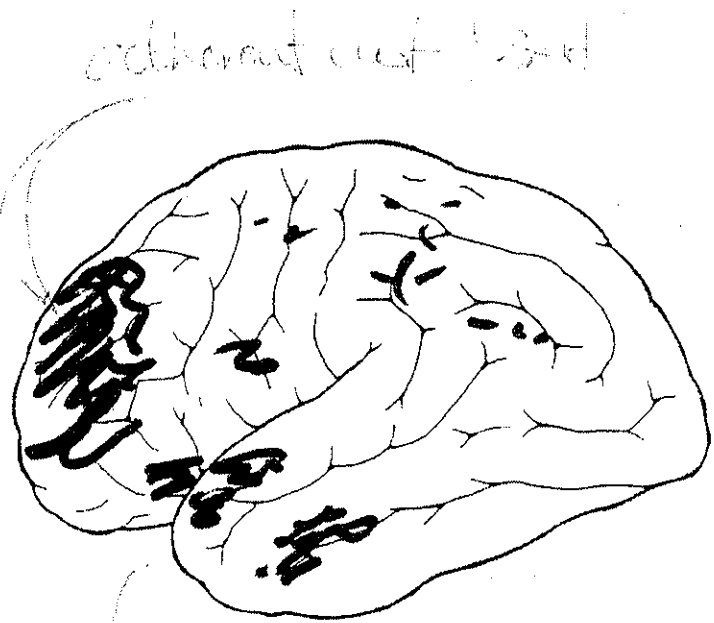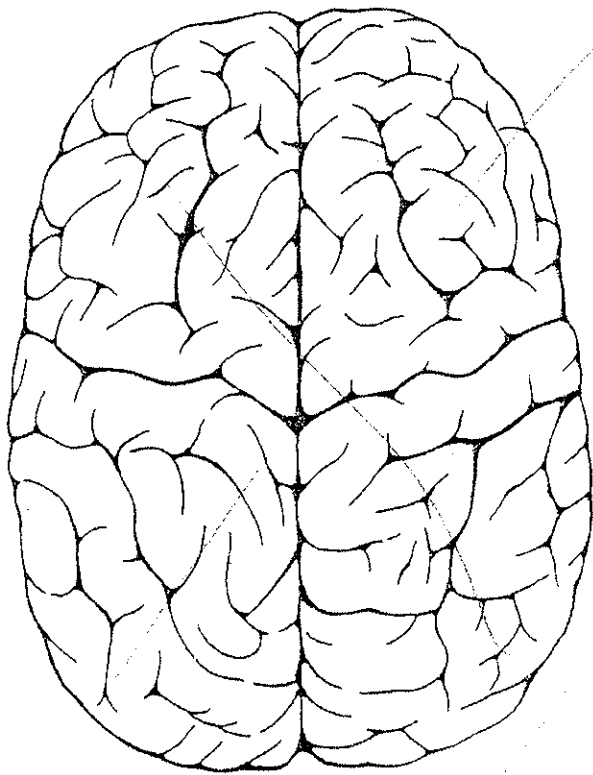
This form may be photocopied.

PAGE ___ OF ___

Brain, superior, inferior, and lateral views

Name Margherita Sabina
Age _____ Race _____ Sex _____

Autopsy No. BCG 1026
Date 2/19/09



areas of contusion

